

Introduction:

Auditory processing deficits affect a significant number of otherwise healthy individuals. They can be more common in patients with certain neurological disorders such as epilepsy. The underlying neural mechanisms of the disorder are not completely understood. Our study was designed to look at fMRI activations associated with processing of auditory stimuli representing variations on the spectrum from pure tones to speech to lay the ground work for further studies in patients with epilepsy.

Methods:

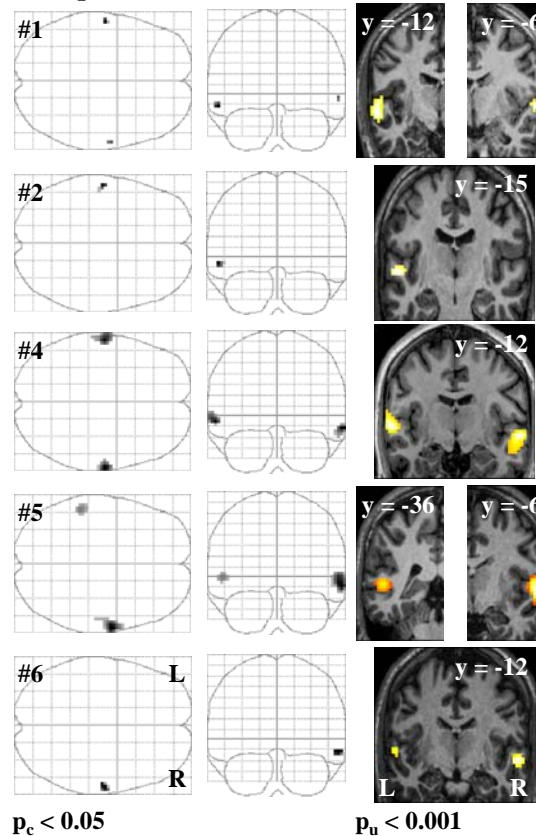
- fMRI scanning (Phillips 1.5T-scanner) on 14 healthy volunteers
- **2 groups** on subjects' baseline performance on a **standardized filtered word recognition test**
- Group 1 (7 subjects) performance within normal limits
- Group 2 (7 subjects) performance 2-3 standard deviations below mean
- All subjects had normal hearing
- **Paradigm:** slow-event related with a combination of short (2.5 seconds) whole-brain clustered-volume acquisitions and sparse temporal sampling (TR = 8sec) to allow auditory stimulus pairs to be presented in the absence of scanner noise
- Stimulus types were: speech (syllables), the 2nd formants of the syllables, frequency modulated tones, and pure tones
- Subjects response via a two-button response pad (same-different).
- **Statistical analyses** for each subject within SPM2, using temporal lobe masks for region of interest analyses (ROI)
- contrast of interest: speech vs. modulated tones
- Coordinates are given in MNI-spaces
- Level of significance of $p_c < 0.05$ (corrected for multiple comparisons)

Results:

In **group 1** five of the seven subjects showed strong superior temporal activations on the lateral bank of Heschl's gyrus. In two cases this activation was left-hemispheric, in two cases right-hemispheric and in one case bilateral (average positions: $-58 \pm 1.7 / -13 \pm 1.7 / -8 \pm 3.5$ and $62.3 \pm 2.9 / -9 \pm 3.5 / -9 \pm 4.2$). One subject with activation on the right Heschl's gyrus showed additional significant activation in the left posterior superior temporal sulcus ($-54 / -36 / 9$).

In **group 2** only three of the seven subjects showed significant activation in the regions of the lateral bank of Heschl's gyrus. In one case the activation was right-hemispheric ($57 / -12 / -15$), in the other two cases it was left-hemispheric (average position: $-57 \pm 4.2 / -7.5 \pm 6.4 / -7.5 \pm 21$). One subject only showed significant activation in the posterior part of the left superior temporal sulcus ($-51 / -45 / 12$).

Group 1 – normal controls



Group 2 – subjects with auditory processing deficit

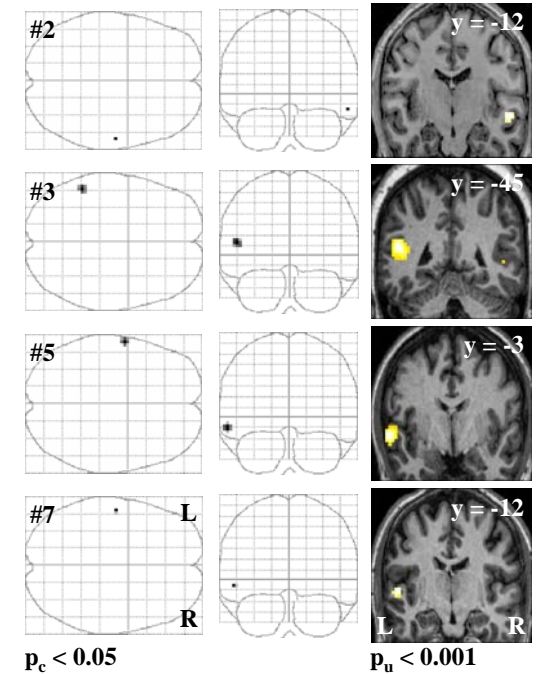


Fig.1: Significantly activated areas in subjects of groups 1 and 2 as glass brain representations ($p_c < 0.05$) or superimposed on the normalized individual anatomical images ($p_u < 0.001$). Coronal slices are positioned at the y-coordinates of the left and right hemispheric Z-value-maxima, indicated in each image. Subjects not represented in this figure showed no significant activations at $p_c < 0.05$.

Conclusion:

Subjects with normal auditory processing show the typical activation of vocal stimuli versus non-vocal stimuli on the lateral bank of Heschl's gyrus [1] centred with a likelihood of about 50% in the right or left hemisphere for stimuli allowing for no semantic processing. Subjects with auditory processing deficits show on average reduced activation in these areas.